Immunohistochemical Methods to Diagnose Atraumatic Spleen Rupture in Feline Infectious Peritonitis of Tiger (*Panthera tigris*)

CRISTINA HORHOGEA, VIOREL FLORISTEAN*, MIRCEA LAZAR, CARMEN CRETU, CARMEN SOLCAN
University of Agricultural Sciences and Veterinary Medicine, Faculty of Veterinary Medicine, 8 M. Sadoveanu Alley, 700489, Iasi, Romania

A body of an eight-year-old male tiger, originated from a Romanian zoo was brought in for pathological diagnosis to the Faculty of Veterinary Medicine. The necropsy revealed uveitis, sero-hemorrhagic peritonitis, fatty liver and kidney, haemorrhagic-necrotic lesions on the spleen, catarrhal enteritis, serous pericarditis and pulmonary anthracosis. Amyloidosis was found in the intestine, liver, lungs and kidney and spleen, associated with necrosis and the presence of hematin blocks. Positive macrophages for feline coronavirus (FCoV) were highlighted by immunohistochemistry in liver, kidney, lungs and intestinal lamina propria. Immunofluorescence (IF) examination of pericardial and peritoneal fluid was positive for feline infectious peritonitis (FIP). Confirmation of FIP coronavirus was made by Reverse Transcription Polymerase Chain Reaction (RT-PCR). The systemic amyloidosis and the presence of hematin in peritoneal fluid and spleen parenchyma are lesions that were not mentioned as specific for FIP until now.

Keywords: immunohistochemistry, immunofluorescence, tiger, feline infectious peritonitis, systemic amyloidosis

Feline infectious peritonitis (FIP) is viral, lethal disease caused by a feline coronavirus, with immune-mediated mechanism. The disease has been reported in a variety of species, mountain lion (*Felis concolor*), caracal (*Caracal caracal*), lion (*Panthera Leo*), tiger (*Panthera tigris*), jaguar (*Panthera onca*), sand cat (*Margarita felis*), shaving (*Lynx lynx*) and cheetah (*Acinonyx jubatus*) [1, 2].

Feline coronaviruses are widespread in domestic and wild cats, being known two biotypes: enteric coronavirus (FECV), non-pathogenic and feline infectious peritonitis virus (FIPV) responsible for the lethal disease (Pedersen, 2009). Less than 10% of coronavirus carriers may develop FIP, as a result of FcoV mutagenic shifts in FIPV. Despite the low incidence, FIP is a major cause of mortality [3, 4].

In coronavirus infection lymphoid organs show T and B lymphocytes depletion, necrotic processes and often their complete involution. Splenic amyloidosis has been described in domestic cats suffering from FIV, associated with marked atrophy of lymphoid follicles [4].

In systemic AA amyloidosis, activated macrophages are producing IL-1 and IL-6 which stimulates hepatocytes to synthesize and secrete serum-A amiloid protein (SAA). During an inflammatory response SAA may increase more than 100 times. However, not all of systemic inflammatory reactions lead to AA-amyloid synthesis. Deposition of insoluble amyloid fibrils appear either due to faulty of enzymatic degradation of SAA or due to an abnormal synthesis of SAA resistant to enzymatic degradation [5]. At cheetahs and Siberian tigers amyloid deposits were found mainly in the medullary interstitium and seldom in glomerular corpuscle [6].

Experimental part

Heart, liver, kidney, spleen, small intestine, lungs fragments were collected, fixed in 10% formalin, embedded in paraffin, sectioned and stained using haematoxylin eosin, Congo red and immunohistochemistry for FIP antibodies. Peritoneal and pericardial fluid were collected on EDTA, centrifuged (2000 rpm for 10 min) and the cells were fixed with ethanol for 20 min. Smears were prepared from fluids and examined by immunofluorescence.

Immunohistochemistry (IHC). Paraffin embedded samples were sectioned at 4 µm thickness, then de-waxed and epitopes were revealed by heating in 10 mmol citric acid buffer (*p*H 6) for 10 min at 95°C in a microwave oven and then left at room temperature for 20 min. Then the slides were washed twice in PBS (*p*H 7.5) for 5 min. Tissue sections were incubated with goat blocking serum, then with primary Pierce monoclonal mouse anti-coronavirus antibodies, Thermo scientific, diluted 1:100 at the room temperature in a humid chamber for one hour. After being washed with PBS, slides were incubated with the secondary antibody, HRP Goat anti Mouse IgG, for 1 hour, in a humid chamber, at 4°C, then washed with PBS and incubated with ABC Kit for 30 min in a humid chamber, then washed with PBS and incubated with DAB substrate for 5 min and counter-stained with Harris haematoxylin, clarified in xylene and mounted [7, 8].

Immunofluorescence was performed on organs sections (prepared like for IHC) and smears from the abdominal and pericardial exudate. In this case we used Sigma secondary antibodies (anti - Cat IgG - FITC antibody produced in goat), diluted 1/50, for one hour, at 37^{0}C in a humidified atmosphere. The smears were incubated with the same anti - coronavirus antibodies and anti - Cat IgG - FITC. The fluorescent complexes were observed using Olympus IX51 inverted microscope.

The coronavirus was identified also using RT-PCR. Viral RNA was extracted from samples using the QIAamp Viral RNA Mini kit, from Qiagen according to the manufacturer‘s protocol. RT-PCR was performed using the One-Step RT-PCR kit (Qiagen) and several pairs of primers (sens and anti-sens). The 205-211 pair (p205: GGCAACCCGAT GTTTAAAACTGG, p211: CACTAGATCCAGACGTTAGCTC) amplified a well conserved region in the group alpha-coronavirus [9]. Amplified DNA fragments were separated by electrophoresis in 2% agarose gel, with *GelPilot DNA Loading Dye*, at 200mA, 80V for one hour. The results were analysed using UV light (Biorad Doc).

* email: vfloristean@uaiasi.ro; Phone: (+40)724040704

Results and discussions

The necropsy of the tiger revealed uveitis, a volume of 1.8 L of sero-hemorrhagic exudate in the peritoneal cavity, a slightly enlarged, blackish-brown, friable spleen, with cracks on the surface and parenchyma looking like a magma on section, mesentery adherent on the spleen surface, kidneys and liver enlarged, yellowish on section, chronic gastrointestinal inflammation, serous pericarditis, lungs with atelectasis and antrachosis.

Microscopic examination of abdominal and pericardial fluid, using fluorescent labeled antibodies, identified positive macrophages for feline coronavirus (fig. 1). Positive macrophages for coronavirus were identified also by immunohistochemistry and immunofluorescence in small intestine (fig. 2), liver, lung and kidneys. In these organs deposits of amyloid were found specifically in the lamina propria and submucosa of the small intestine, in the Malpighi corpuscles and proximal convoluted tubules, in lung parenchyma (fig. 3) and in the blood vessels media from lungs. Spleen showed liquefaction necrosis, with yellow-brownish haematin fragments, negative at Perls stain (fig. 4).

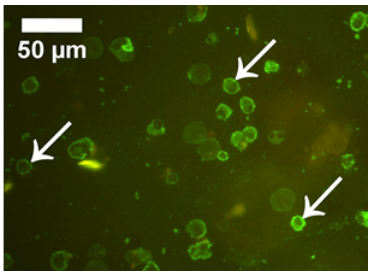

Fig. 1. Macrophages and lymphocytes positives for FCoV antibodies (arrows) in pericardial fluid. Direct immunofluorescence test

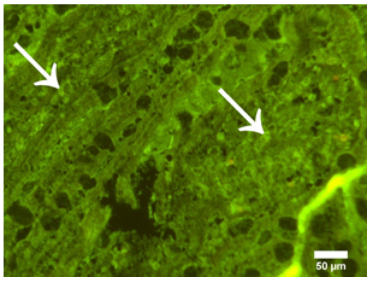

Fig. 2. Macrophages and lymphocytes positives for FCoV antibodies (arrows) in small intestine lamina propria. Direct immunofluorescence test.

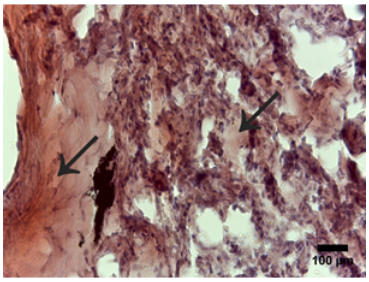

Fig. 3. Lung amyloidosis: amyloid deposits in arteriolar wall and pulmonary parenchima (arrows). Congo red stain.

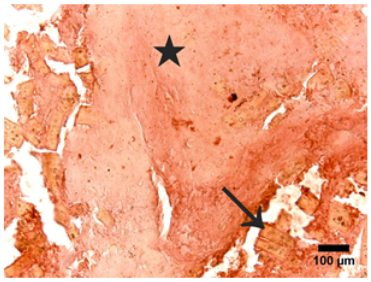

Fig. 4. Spleen amyloidosis: amyloid deposits (star) and hematin blocks (arrow). Stain Congo red.

Feline infectious peritonitis is difficult to diagnose clinically because each animal can display symptoms that are similar to those of many other diseases [10]. The symptoms generally include chronic weight loss, depression, uveitis, anemia and persistent fever that does not respond to antibiotic treatment. Feline infectious peritonitis can evolve in wet or dry form. Wet form of FIP is characterized by an accumulation of fluid in the abdomen, rarely in the pleural cavity. In our case we have found liquid in pericardial cavity. Early in the disease, the animal exhibited symptoms similar to the dry form, including weight loss, fever, loss of appetite, and lethargy.

Animals that were initially exposed to FCoV are often asymptomatic. Only a small proportion of animals exposed to FCoV develop FIP, and this can occur weeks, months or even years after initial exposure. Although the two forms of FCoV are hardly differentiated, acquisition of the tropism for macrophages allowed us to establish that the virus we identified by RT-PCR, immunofluorescence and IHC is FIPV because the enteric form of coronavirus can be observed only in intestinal epithelial cells [4].

Using anti feline coronavirus antibodies allowed confirmation of FIP by IF and IHC.

Inflammatory and degenerative neoplastic lesions are often caused by infectious agents, including feline leukemia virus, feline immunodeficiency virus, feline infectious peritonitis virus and *Helicobacter spp.* all known as major pathogens in captive and wild cat populations [11, 12].

In our case the histopathological exam revealed the liquefaction necrosis of spleen parenchyma and systemic amyloidosis. Amyloidosis was massive in renal corpuscles and intercellular in some renal tubule. We also observed cortical tubular epithelial cell degeneration, cytoplasm vacuolation and some nucleus pyknosis.

The deposition of amyloid in the renal medullar interstitium, the liver sinusoids capillary, along the gastrointestinal tract *lamina propria* and endocrine organs is well documented. The occurrence of amyloidosis is related to some inflammatory disease such as chronic gastritis. The systemic AA amyloidosis in the intestine, lung, liver, kidney is very common and cause of death in many captive populations [6,10]. Although medullary renal amyloidosis occurs frequently, it is less dangerous for kidney function and thus less important than glomerular deposition of amyloid as was observed in our case.

The extensive amyloid deposition in spleen could be the cause of splenic parenchyma atrophy and lead to ischemia and necrosis. Also amyloidosis predispose to splenic rupture because of parenchyma and blood vessels fragility [13, 14]. The presence of hematin, a chemical compound with the incomplete indicated structure, in spleen and peritoneal fluid is a result of hemoglobin breakdown product during intravascular hemolysis of hemolytic major crises in spleen. Because in this pigment iron is embedded in an organic complex, hematin Perls reaction is negative [15].

Conclusions

In conclusion, chronic coronavirus infection in felines can cause systemic amyloidosis, multiple splenic infarcts and atraumatic rupture of the spleen which explains the presence of hematin in parenchyma and peritoneal fluid collection.

References

1.MWASE, M., SHIMADA, K., MUMBA, C., YABE, J., SQUARRE, D., MADARAME, H., Journal of Comparative Pathology, **152**, 2015, p. 265

2.STEPHENSON, N., SWIFT, P., MOELLER, R.B., WORTH, S.J, FOLEY, J., Journal of Wildlife Diseases, **49**, 2013, p. 408

3.BROWN, M.A., Veterinary Immunology and Immunopathology, **143**, 2011, p. 265

4.KIPAR, A., MELI, M.L., BAPTISTE, K.E., BOWKER, L.J., LUTZ, H., Journal of General Virology, **91**, 2010, p. 1698

5.NEWKIRK, K.M., NEWMAN, S., WHITE, L., ROHRBACH, B., RAMSAY, E., Veterinary Pathology, **48**, 2011, p. 698

6.WOLDEMESKEL, M., Veterinary Medicine International, 2012, 427296.
7.CIPU, D, BERCEANU VADUVA, D.M., VELIMIROVICI, D.E., CIPU, D.S., Rev. Chim. (Bucharest), **67**, no. 6, 2016, p. 1218
8.IACOB, A., SIN, A., MOCAN, S., ORMENISAN, A., COMANEANU, R.M., HANCU, V., FULOP, E., TILINCA, M., Rev. Chim. (Bucharest), **67,** no. 10, 2016, p. 2028
9.HERREWEGH, A.A., DE GROOT, R.J., CEPICA, A., EGBERINK, H.F., HORZINEK, M.C., ROTTIER, P.J., J. Clin Microbiol., **33(3)**, 1995, p. 684
10.PEDERSEN, N.C., Journal of Feline Medicine and Surgery, **11**, 2009, p. 225
11.JUNGINGER, J., HANSMANN, F., HERDER, V., LEHMBECKER, A., PETERS, M., BEYERBACH, M., WOHLSEIN, P., BAUMGARTNER, W., PLoS ONE, **10**, 2015, e0130573.
12.SONMEZ, G., AYTUG, N., AKKOC, A., CIHAN, H., ALASONYALILAR, A., European Journal of Wildlife Research, **54**, 2007, p. 385
13.CHAU, E.M., CHAN, A.C., CHAN, W.K., Amyloid, **15**, 2008, p. 213
14.RENZULLI, P., HOSTETTLER, A., SCHOEPFER, A., GLOOR, B., CANDINAS, D., British Journal of Surgery, **96**, 2009, p. 1114
15.GULATI, R., MENON, M.P., Blood, **125**, 2015, p. 3664

Manuscript received: 11.12.2016